International Journal of Multiphysics
Volume 18, No. 3, 2024
ISSN: 1750-9548

Radiofrequency Ablation and Surgical Management of Benign Solitary Thyroid Nodules: A Narrative Review

Samir Ibrahim Mohamed, Mohamed Farouk Amin , Sameh Saber Bayoumi , Taha Mahfouz Abdelaleem, Abdelbaset Mohamed Elsayed

Department of General Surgery, Faculty of Medicine, Zagazig University, Egypt

***Corresponding author: Taha Mahfouz Abdelaleem,**

Abstract

Background: Benign solitary thyroid nodules may cause compressive symptoms or cosmetic complaints requiring treatment. Ultrasound is the primary imaging modality for thyroid nodule evaluation because it detects nonpalpable nodules, characterizes nodule morphology, guides fine-needle aspiration, and evaluates cervical lymph nodes. Surgical management remains an important option when complete excision is preferred or diagnostic certainty is required. Radiofrequency ablation (RFA) is a minimally invasive, ultrasound-guided technique that offers targeted nodule treatment while preserving surrounding thyroid tissue.

Aim: This narrative review aims to discuss the assessment and management of benign solitary thyroid nodules, with particular emphasis on surgical intervention and RFA techniques, their indications, efficacy, complications, preservation of thyroid function, and follow-up.

Conclusion: Surgery provides definitive removal and histopathological evaluation of thyroid nodules but may be associated with neck scarring, hypothyroidism, and operative complications. RFA offers a minimally invasive alternative for appropriately selected, confirmed benign nodules, with the potential for symptom and cosmetic improvement while preserving thyroid tissue. Treatment selection should integrate cytological and ultrasound findings, clinical symptoms, nodule characteristics, and patient preference. Continued follow-up is important after RFA to assess treatment response, residual viable tissue, and regrowth.

Keywords: Benign thyroid nodules; Radiofrequency ablation; Thyroid lobectomy; Ultrasound; Thyroid function; Thermal ablation.

Introduction

A thyroid nodule is a discrete lesion within the thyroid gland that is radiologically distinct from the surrounding thyroid parenchyma. This definition depends mainly on imaging, particularly ultrasound, because palpation alone may detect irregularity or enlargement without proving that a true nodule exists. A nodule may be solitary or multiple and may show solid, cystic, mixed, or spongiform composition. In a study focused on solitary thyroid nodules, the term should therefore refer to one clearly identifiable thyroid lesion rather than diffuse thyroid enlargement or multinodular goiter [(1)].

Surgical management of solitary thyroid nodules involves operative removal of the affected thyroid tissue, usually by hemi-thyroidectomy when the disease is confined to one thyroid lobe. The main goals are to remove the target nodule, relieve local symptoms, improve cosmetic deformity when present, and obtain a definitive histopathological diagnosis. Although many benign thyroid nodules can be followed conservatively or treated by minimally invasive techniques, surgery remains an important option when complete excision is preferred or when diagnostic certainty is required [(2)].

Radiofrequency ablation is an ultrasound-guided thermal ablation technique that uses alternating electrical current delivered through an electrode to generate frictional heat within the target nodule. The heat produces coagulative necrosis, vascular thrombosis, fibrosis, and gradual nodule volume reduction. [3].

Solitary Thyroid Nodules

Definition of Thyroid Nodule:

A thyroid nodule is a discrete lesion within the thyroid gland that is radiologically distinct from the surrounding thyroid parenchyma. This definition depends mainly on imaging, particularly ultrasound, because palpation alone may detect irregularity or enlargement without proving that a true nodule exists. A nodule may be solitary or multiple and may show solid, cystic, mixed, or spongiform composition. In a study focused on solitary thyroid nodules, the term should therefore refer to one clearly identifiable thyroid lesion rather than diffuse thyroid enlargement or multinodular goiter [1].

Causes of Thyroid Nodules:

Thyroid nodules may result from benign hyperplastic processes, inflammatory disease, benign neoplasia, functioning thyroid tissue, or malignancy. Common benign causes include colloid nodules, adenomatous nodules, follicular adenomas, cystic degeneration, multinodular goiter with a dominant nodule, and thyroiditis-related nodularity. Malignant causes include papillary thyroid carcinoma, follicular carcinoma, medullary thyroid carcinoma, poorly differentiated carcinoma, anaplastic carcinoma, lymphoma, and metastatic disease to the thyroid [1].

Diagnosis of Benign Solitary Thyroid Nodules:

Diagnosis of a benign solitary thyroid nodule requires more than detecting a single thyroid lesion. The nodule should be solitary on ultrasound, should not have suspicious cervical lymph nodes or metastatic features, and should have cytology consistent with benign disease. Bethesda II cytology supports benign diagnosis and includes follicular nodular disease, colloid nodule, Hashimoto thyroiditis in the correct context, and subacute granulomatous thyroiditis. However, clinical and ultrasound correlation remains necessary because false-negative cytology is possible [4].

A benign diagnosis becomes stronger when cytology, ultrasound, and clinical findings are concordant. Repeat benign cytology substantially reduces the likelihood of malignancy and supports surveillance or benign nodule treatment. Discordance between benign cytology and high-risk ultrasound features should prompt repeat FNA or additional evaluation rather than immediate treatment as a benign nodule. This is important before RFA, because ablation should be reserved for confidently benign nodules [5].

In symptomatic benign solitary nodules, the final diagnosis and treatment decision should integrate cytology, TIRADS category, nodule size, symptoms, cosmetic complaint, thyroid function, and patient preference. Surgery may be selected when there is diagnostic uncertainty, large size, compressive symptoms, substernal or retroclavicular extension, or patient preference for excision. RFA may be selected for confirmed benign nodules when the aim is symptom improvement, cosmetic improvement, and thyroid tissue preservation [5,1].

Clinical Presentation of Solitary Thyroid Nodules:

Most solitary thyroid nodules are clinically silent and are discovered incidentally during imaging performed for unrelated reasons. When clinically apparent, patients may present with an anterior neck swelling, a palpable thyroid mass, visible asymmetry, local pressure, discomfort, or cosmetic complaint. Most patients with thyroid nodules are euthyroid, because the majority of nodules do not produce clinically significant thyroid hormone excess or deficiency [1].

The clinical presentations and relevant differentials of solitary thyroid nodules can be summarised as follows:

Asymptomatic nodules: usually discovered incidentally on imaging; most are small and low-risk.

Compressive symptoms: dysphagia, dyspnea, choking sensation, or neck pressure, more likely with large or posterior nodules.

Cosmetic concerns: visible anterior neck swelling or asymmetry, a recognised indication for treating benign nodules.

Enlarging nodules: significant growth requiring reassessment for repeat ultrasound, repeat FNA, or treatment.

Differential diagnoses of anterior neck masses: thyroidal (cyst, multinodular goiter, adenoma, carcinoma) and non-thyroidal (thyroglossal duct cyst, lymphadenopathy, branchial cleft cyst, and other soft-tissue lesions) [5].

Risk Assessment of Thyroid Nodules:

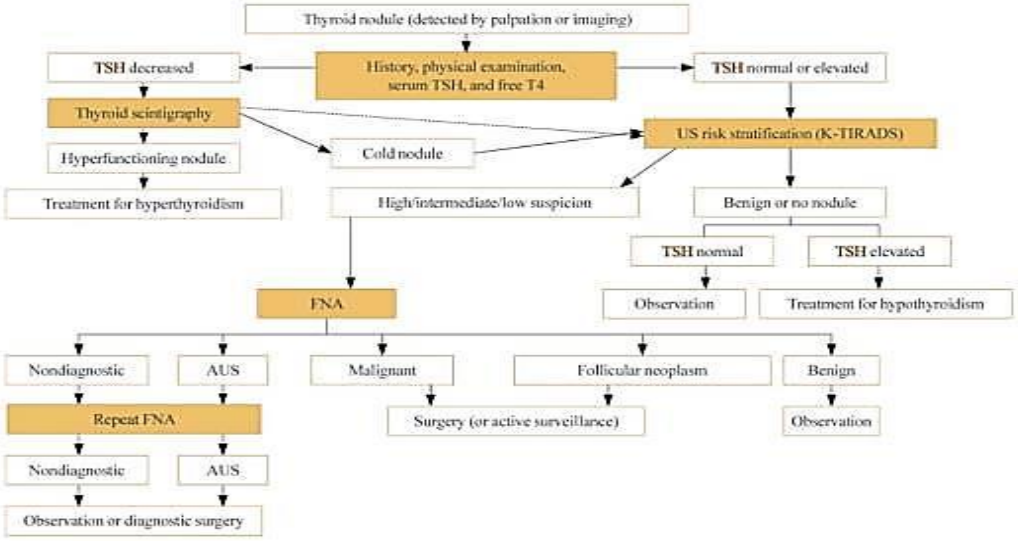

Figure 1. Initial evaluation algorithm for thyroid nodules with suspicious US features [6].

Risk assessment begins with history, physical examination, TSH measurement, and thyroid and neck ultrasound. History should evaluate radiation exposure, family history of thyroid cancer, rapid growth, compressive symptoms, hoarseness, thyroid dysfunction symptoms, and previous thyroid disease. Physical examination should assess nodule size, consistency, mobility, fixation, tenderness, lymphadenopathy, and voice quality [1]. (Figure 1).

Ultrasound-based risk assessment provides the main imaging framework for thyroid nodule evaluation. Suspicious sonographic features such as marked hypoechogenicity, irregular margins, microcalcifications, nonparallel orientation, and suspicious lymph nodes increase concern for malignancy.

TIRADS systems organize these features into categories that help determine FNA need and follow-up interval. This reduces unnecessary biopsies while preserving sensitivity for clinically important malignancy [7,8].

Laboratory assessment also contributes to risk assessment. TSH should be measured initially because a suppressed TSH may suggest an autonomously functioning nodule, which is usually benign and may require scintigraphy rather than immediate FNA. In contrast, normal or elevated TSH usually leads to ultrasound-based risk stratification and FNA decision-making. Overall, thyroid nodule risk assessment should integrate clinical, biochemical, ultrasound, cytological, and patient-related factors [5,1].

Ultrasound Evaluation of Thyroid Nodules:

Ultrasound is the primary imaging modality for thyroid nodule evaluation because it detects nonpalpable nodules, characterizes nodule morphology, guides FNA, and evaluates cervical lymph nodes. Diagnostic ultrasound should be performed when nodular thyroid disease is clinically suspected or when a thyroid nodule is incidentally identified on another imaging modality. The examination should include both thyroid lobes, isthmus, thyroid bed, central neck, and lateral cervical compartments [5].

A complete ultrasound report should describe nodule size, location, composition, echogenicity, margins, shape or orientation, echogenic foci, vascular or structural relationships, and suspicious cervical lymph nodes. Standardization is important because clinical decisions depend on precise interpretation of sonographic features. Inconsistent terminology may lead to unnecessary biopsy in benign nodules or missed biopsy in suspicious nodules [8].

Ultrasound also has a role beyond diagnosis. It guides FNA needle placement, monitors growth over time, assesses response after RFA, and detects recurrence or post-treatment changes. In patients selected for RFA, ultrasound is essential before treatment to define the target nodule and during treatment to monitor the ablation zone and protect nearby structures. After treatment, ultrasound allows objective assessment of volume reduction or residual viable tissue [8,5]. (Figure 2).

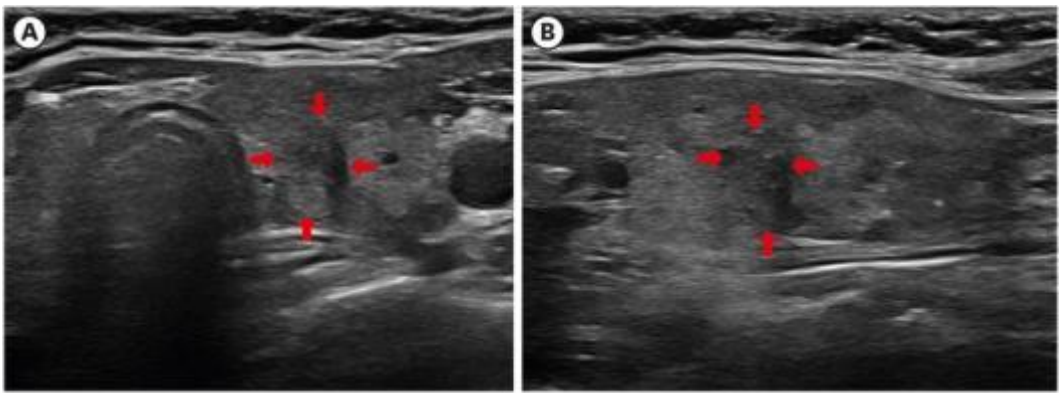

Figure 2. Ultrasonography of the left thyroid nodule. A 0.84×1.01×0.74 cm sized nodule on the mid portion of the left thyroid gland. Outside fine needle aspiration revealed papillary thyroid carcinoma. The axial view shows a long axis of 1.01 cm (A), and the longitudinal view shows a long axis of 0.74 cm (B). Red arrows indicate the boundary of the nodule [9].

Ultrasound findings must be interpreted with the clinical context. A small low-risk nodule may not require FNA, while a nodule with suspicious lymph nodes or extrathyroidal extension may require biopsy even if small. Likewise, benign cytology is reassuring, but high-risk ultrasound features with benign cytology may require repeat FNA. Therefore, ultrasound is central but should not be separated from clinical and cytological data [5,1]. (Figure 2).

Nodule Size:

Nodule size should be measured in 3 dimensions because single-diameter measurement may not fully reflect nodule burden. Volume estimation is particularly useful for follow-up and for evaluating treatment response after ablation. In RFA, baseline volume and follow-up volume are used to calculate volume reduction rate, which is one of the main indicators of treatment efficacy. Accurate size measurement therefore affects both diagnosis and outcome evaluation[8].

Sonographic Features of Benign Nodules:

The remaining sonographic features are best consolidated as benign properties that argue against malignancy:

Echogenicity: iso- or hyperechoic nodules favour benignity, whereas marked hypoechogenicity is the suspicious feature to be excluded.

Calcification: comet-tail artifact and coarse macrocalcifications suggest a benign colloid nodule, while punctate microcalcifications must be excluded.

Contour: smooth, well-defined margins favour benignity; irregular or spiculated margins exclude a benign call.

Halo: a thin, complete, regular halo is a reassuring benign sign.

Composition (cystic vs. solid): spongiform and predominantly cystic nodules carry a low malignancy risk [8].

Ultrasound Risk Stratification Systems:

Ultrasound risk stratification systems were created to standardize thyroid nodule assessment and reduce subjective reporting. They group nodules according to ultrasound features associated with malignancy risk and guide whether FNA, follow-up, or no further evaluation is appropriate. Common systems include EU-TIRADS, ACR TI-RADS, K-TIRADS, ATA ultrasound patterns, and other regional risk stratification systems [7].

These systems help reduce unnecessary FNA by matching biopsy thresholds to the expected risk of malignancy. For example, a low-risk nodule generally requires a larger size before FNA, while a high-risk nodule may require

biopsy at a smaller size. Risk stratification systems also help communicate findings between radiologists, endocrinologists, surgeons, and interventional radiologists using a shared language [5,8].

TIRADS Classification Scheme for Thyroid Nodules:

ACR-TIRADS classifies thyroid nodules according to increasing risk of malignancy. ACR -TIRADS 1 indicates a normal thyroid gland with completely cystic nodule. ACR -TIRADS 2 includes benign patterns such as pure cysts and entirely spongiform nodules (m

ixed cystic). ACR -TIRADS 3 includes low-risk nodules that are iso or hyperechoic without high suspicion features. ACR -TIRADS 4 includes intermediate-risk mildly hypoechoic nodules without high suspicion features [5].

ACR -TIRADS 5 includes high-risk nodules with at least one high suspicion feature, including irregular shape, irregular margins, microcalcifications, or marked hypoechogenicity. FNA indications depend on the EU-TIRADS category and size threshold. For example, lower-risk nodules require larger size thresholds before FNA is recommended, while high-risk nodules are biopsied at smaller sizes. Suspicious lymph nodes or extrathyroidal extension may prompt biopsy regardless of the usual size threshold [5,7].

TIRADS classification is important in the current study context because patients with benign solitary nodules and lower-risk TIRADS categories are candidates for conservative, surgical, or minimally invasive management depending on symptoms and patient preference. High-risk TIRADS categories generally require exclusion of malignancy before RFA or benign nodule treatment is considered. Therefore, TIRADS helps define eligibility and supports safe selection of patients for intervention [5].

Fine-Needle Aspiration Cytology:

Fine-needle aspiration cytology is one of the central diagnostic tools for thyroid nodules. It provides cytological classification that helps distinguish benign nodules from indeterminate, suspicious, or malignant lesions. FNA is generally performed after clinical, biochemical, and ultrasound assessment, because not every detected nodule requires biopsy. The decision to perform FNA depends on nodule size, ultrasound risk category, suspicious lymph nodes, clinical risk factors, and patient-specific context [5,1].

Bethesda System Diagnostic Categories for Reporting Thyroid Cytopathology:

Bethesda I refers to non diagnostic or inadequate specimens, while Bethesda II represents benign cytology, including follicular nodular disease, colloid nodule, Hashimoto thyroiditis in the proper context, and subacute granulomatous thyroiditis. Bethesda III describes atypia of undetermined significance, while Bethesda IV indicates follicular neoplasm. Bethesda V is suspicious for malignancy, and Bethesda VI is malignant. These categories provide a common language between cytopathologists and treating clinicians [4].

Approach to the Adult Patient with a Thyroid Nodule:

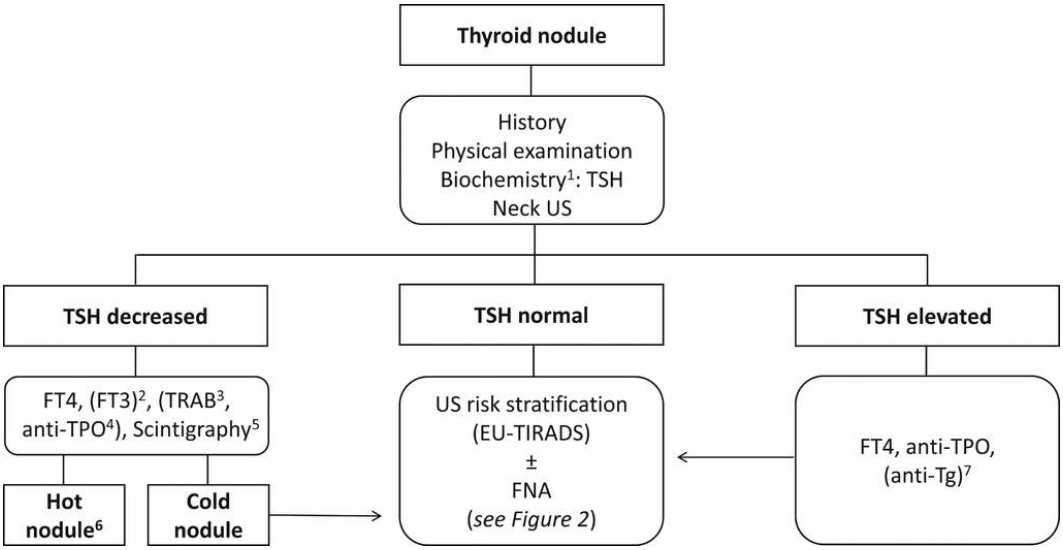

Figure 3. Management schedule for thyroid nodules [(5)].

Surgical management of solitary thyroid nodules involves operative removal of the affected thyroid tissue, usually by hemi-thyroidectomy when the disease is confined to one thyroid lobe. The main goals are to remove the target nodule, relieve local symptoms, improve cosmetic deformity when present, and obtain a definitive histopathological diagnosis. Although many benign thyroid nodules can be followed conservatively or treated by minimally invasive techniques, surgery remains an important option when complete excision is preferred or when diagnostic certainty is required [(2)]. (Figure 3).

Indications for Surgical Intervention:

Surgical intervention is indicated when a thyroid nodule is malignant, suspicious for malignancy, cytologically indeterminate and unsuitable for active surveillance, progressively enlarging, symptomatic, or cosmetically disturbing. In benign nodules, surgery may be considered when the nodule causes airway compression, esophageal compression, choking sensation, dysphagia, dyspnea, retroclavicular extension, mediastinal extension, visible deformity, or persistent patient concern. Thus, benign cytology does not automatically exclude the need for surgery if the nodule produces clinically relevant structural or cosmetic effects [(5)].

Preoperative Evaluation:

Preoperative evaluation aims to confirm the diagnosis, define surgical indication, determine operative extent, reduce perioperative risk, and establish baseline clinical and laboratory status. It includes detailed history, physical examination, thyroid function assessment, neck ultrasound, biopsy assessment, review of comorbidities, medication review, anesthetic assessment, and voice evaluation when indicated. Careful evaluation is important because thyroid surgery takes place near the airway, major vessels, parathyroid glands, and laryngeal nerves [(2)].

History Taking:

History taking should document the onset of the neck swelling, duration, growth rate, pain, local pressure symptoms, dysphagia, dyspnea, choking sensation, cough, hoarseness, voice fatigue, cosmetic concern, symptoms of thyroid dysfunction, previous thyroid disease, previous neck surgery, childhood or therapeutic neck irradiation, family history of thyroid malignancy, medication use, anticoagulant intake, and bleeding tendency. Rapid enlargement, fixation, cervical lymphadenopathy, hoarseness, and previous radiation exposure are important warning features that may increase suspicion and alter surgical planning [(5,2)].

Physical Examination:

Physical examination should assess the thyroid swelling for site, size, consistency, tenderness, mobility, surface, relation to swallowing, and visible cosmetic deformity. The examination should also include cervical lymph nodes, tracheal position, voice quality, signs of airway or esophageal compression, and clinical signs of thyroid dysfunction.

A hard fixed nodule, suspicious lymphadenopathy, abnormal voice, or tracheal deviation may suggest higher-risk disease or increased operative complexity [2].

Laboratory Assessment:

Laboratory assessment before thyroid surgery includes thyroid function tests, especially TSH, free T3, and free T4. These tests determine whether the patient is euthyroid, hyperthyroid, or hypothyroid before surgery. Elective thyroid surgery is preferably performed in a euthyroid state because uncontrolled hyperthyroidism may increase the risk of perioperative tachyarrhythmia, thyrotoxicosis, and thyroid storm. Antithyroid medications, beta-blockers, and sometimes iodine preparations may be used before surgery when needed [2].

Baseline thyroid function is also needed for postoperative comparison after hemi-thyroidectomy.

Imaging Studies:

Neck ultrasound is the main imaging study before thyroid surgery. It confirms the thyroid origin of the lesion, determines whether it is solitary or part of multinodular disease, measures nodule size, evaluates sonographic risk features, detects suspicious cervical lymph nodes, and guides FNA when indicated. CT or MRI may be added when there is suspected retrosternal extension, mediastinal extension, airway compression, esophageal compression, or distorted anatomy that cannot be fully evaluated by ultrasound [5,2].

Biopsy Assessment:

Biopsy assessment is usually performed by ultrasound-guided fine-needle aspiration cytology when a thyroid nodule meets criteria for sampling. Cytology classifies nodules as benign, indeterminate, suspicious, or malignant, and this classification has a direct effect on the decision for surgery. Benign cytology may support surgery for compression or cosmetic indications, while suspicious or malignant cytology generally supports surgical excision for definitive diagnosis and treatment [5,2].

Indirect Laryngoscopy:

Indirect laryngoscopy or flexible fiberoptic laryngoscopy is recommended when there is preoperative hoarseness, voice change, previous neck surgery, suspected invasive disease, or concern about vocal cord dysfunction. It documents baseline vocal cord mobility before surgery and helps distinguish pre-existing vocal cord paralysis from postoperative recurrent laryngeal nerve injury. This is clinically important because postoperative voice changes are among the most meaningful functional complications after thyroid surgery [2,10].

Hemi-Thyroidectomy:

Hemi-thyroidectomy, or thyroid lobectomy, is the removal of one thyroid lobe and often the isthmus. It is commonly used for unilateral benign thyroid nodules, selected indeterminate nodules, and selected low-risk malignant nodules. For solitary benign thyroid nodules, it provides complete removal of the affected lobe while preserving the opposite lobe, which may continue to maintain thyroid hormone production after surgery [2].

Preservation of Critical Structures During Surgery:

Preservation of critical structures is a central objective of thyroid surgery. The surgeon must protect the recurrent laryngeal nerve to preserve vocal cord movement, the external branch of the superior laryngeal nerve to preserve pitch control, the parathyroid glands to maintain calcium homeostasis, and the thyroid vessels to avoid bleeding while preserving parathyroid vascularity. This requires capsular dissection, direct visualization, controlled traction, and careful use of thermal energy [2,11]. (Figure 4).

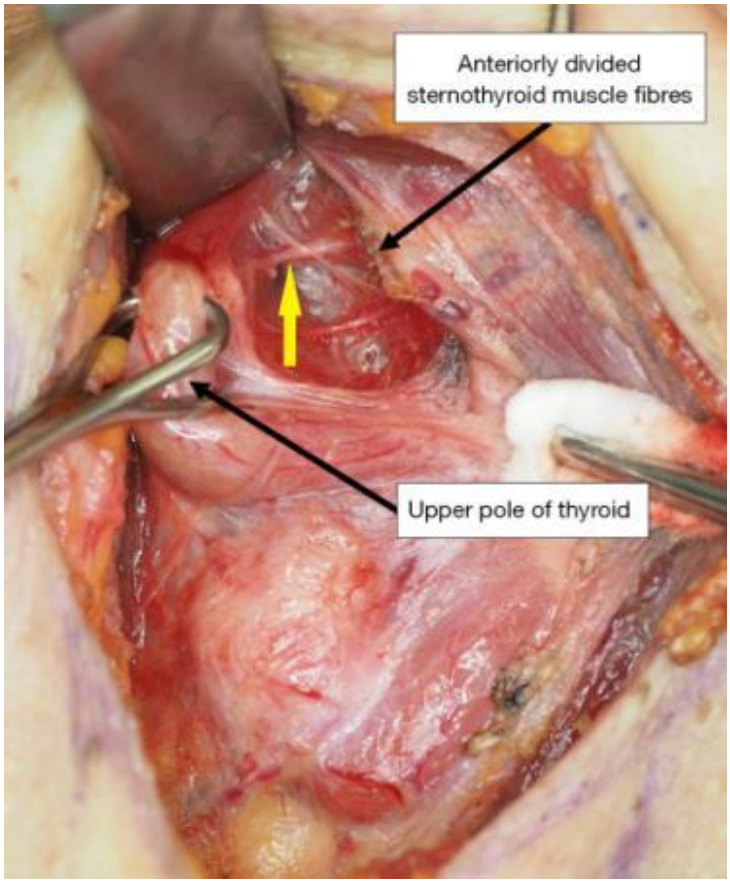

Figure 4. Right thyroidectomy showing exposure of the external branch of the superior laryngeal nerve [(12)].

Recurrent Laryngeal Nerve:

Injury to the recurrent laryngeal nerve may occur through traction, compression, transection, thermal injury, ligation, or compromised blood supply. (Figure 4).

Temporary injury may cause hoarseness that improves with time, while permanent injury may lead to persistent vocal cord paralysis. [(10)].

Parathyroid Glands:

Parathyroid preservation requires both anatomical identification and vascular preservation [(2)].

Thyroid Blood Vessels:

During surgery, the superior pole vessels are controlled close to the thyroid capsule to protect the external branch of the superior laryngeal nerve, while the inferior thyroid artery branches are handled carefully because of their relation to the recurrent laryngeal nerve and parathyroid blood supply. The middle thyroid vein should be ligated when encountered during lateral mobilization. [(2,11)].

Surgical Adjunct: Intraoperative Neuromonitoring

Intraoperative neuromonitoring is used as an adjunct to help identify and functionally assess the recurrent laryngeal nerve during thyroid surgery. [(2)]. (Figure 5).

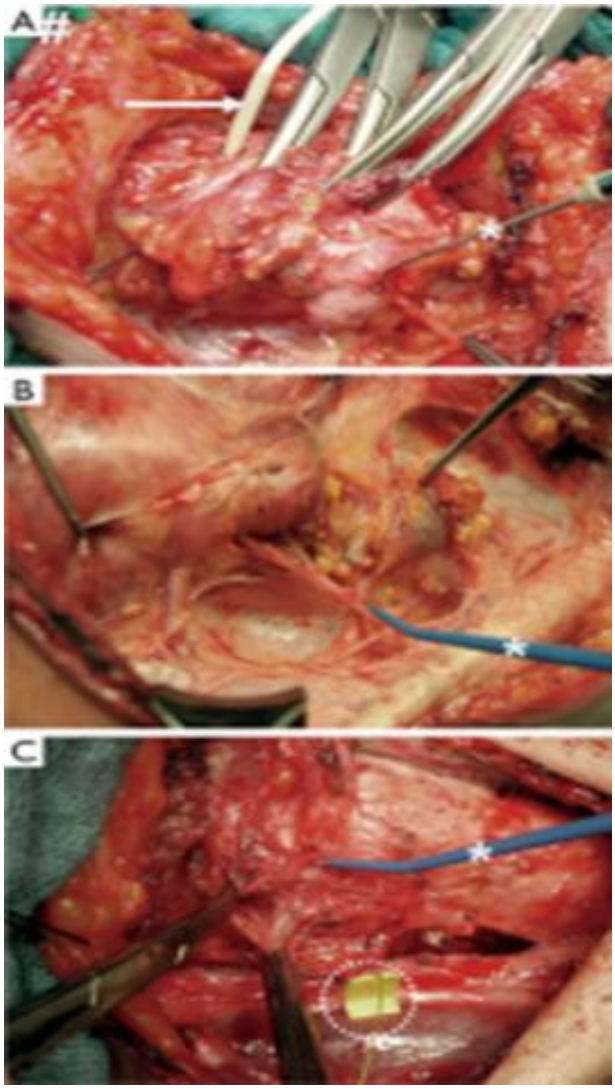

Figure 5. Intraoperative nerve monitoring during thyroidectomy [13]

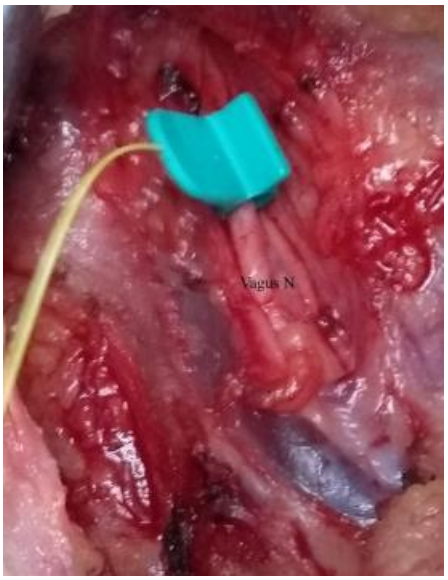

Figure 6. Automatic Periodic Stimulation (APS) electrode mounted around the vagus nerve [14].

Postoperative Care After Thyroid Surgery:

Postoperative care after thyroid surgery focuses on airway safety, bleeding detection, pain control, voice assessment, calcium monitoring, wound assessment, and thyroid function follow-up. [2]. (Figure 6).

Calcium and parathyroid hormone assessment may be required depending on the extent of surgery and institutional protocol. [15,2].

Complications of Thyroid Surgery:

Hematoma:

Severe hematoma requires urgent recognition and may need immediate wound opening, airway control, evacuation, and definitive hemostasis [2].

Wound Infection:

Early recognition and appropriate antibiotics or drainage are needed when infection develops [2].

Skin Scar:

Careful incision placement, atraumatic flap handling, layered closure, and subcuticular skin closure can improve cosmetic results [2].

Hypocalcaemia:

Postoperative calcium monitoring is therefore important when parathyroid injury is suspected [2].

Symptomatic hypocalcaemia is treated with calcium supplementation, and severe cases may require intravenous calcium and inpatient monitoring [16,2].

Recurrent Laryngeal Nerve Injury:

Prevention requires identification of the nerve, careful dissection near the tracheoesophageal groove, avoidance of blind clamping, cautious control of inferior thyroid artery branches, and avoidance of excessive traction or thermal spread. The nerve should be followed safely toward its laryngeal entry point when needed [2,10].

Voice Changes:

Recurrent laryngeal nerve injury may cause hoarseness and vocal cord paralysis, while external branch injury may cause loss of high-pitched voice, vocal fatigue, and reduced pitch control. [2,11].

Hypothyroidism:

Hypothyroidism after hemi-thyroidectomy occurs when the remaining thyroid lobe cannot fully compensate for the removed lobe. [15].

Pain:

Pain is usually greatest in the early postoperative period and may affect swallowing, neck movement, sleep, discharge readiness, and patient satisfaction. [2].

Cosmetic Concerns:

Cosmetic concerns after surgical intervention are mainly related to the anterior neck scar. [2,17].

Hospital Stay After Thyroid Surgery:

Many selected patients can be discharged on the same day or the next day. [2].

Recurrence after Surgical Management:

Recurrence after surgical management of a solitary benign thyroid nodule is usually related to residual thyroid tissue, development of nodules in the remaining lobe, or an underlying multinodular tendency that was not initially apparent. [2].

Radiofrequency Ablation and Comparative Evaluation with Surgery

Minimally invasive techniques differ from surgery in both mechanism and clinical outcome. Surgery removes thyroid tissue immediately and provides complete histopathological examination, while ablation destroys the target tissue in situ and produces gradual shrinkage over time. [18].

Radiofrequency Ablation:

Radiofrequency ablation is an ultrasound-guided thermal ablation technique that uses alternating electrical current delivered through an electrode to generate frictional heat within the target nodule. The heat produces coagulative necrosis, vascular thrombosis, fibrosis, and gradual nodule volume reduction. [3].

Basic Principles of Radiofrequency Ablation:

The basic principle of thyroid RFA is to ablate the target nodule as completely as possible while preserving adjacent normal thyroid tissue and surrounding critical structures. This is achieved through continuous ultrasound visualization, controlled electrode movement, careful power adjustment, and treatment of the nodule unit by unit. The aim is not immediate disappearance of the nodule, but progressive shrinkage as necrotic tissue is resorbed and replaced by fibrosis [3].

Modern thyroid RFA depends on several technical principles that improve efficacy and safety. These include the transisthmic approach, moving-shot technique, continuous visualization of the electrode tip, hydrodissection when needed, and attention to vascular supply at the nodule margin. These maneuvers help reduce undertreatment of peripheral viable tissue and decrease the risk of thermal injury to the recurrent laryngeal nerve, vagus nerve, trachea, esophagus, vessels, skin, and strap muscles [19,3]. (Figure 7).

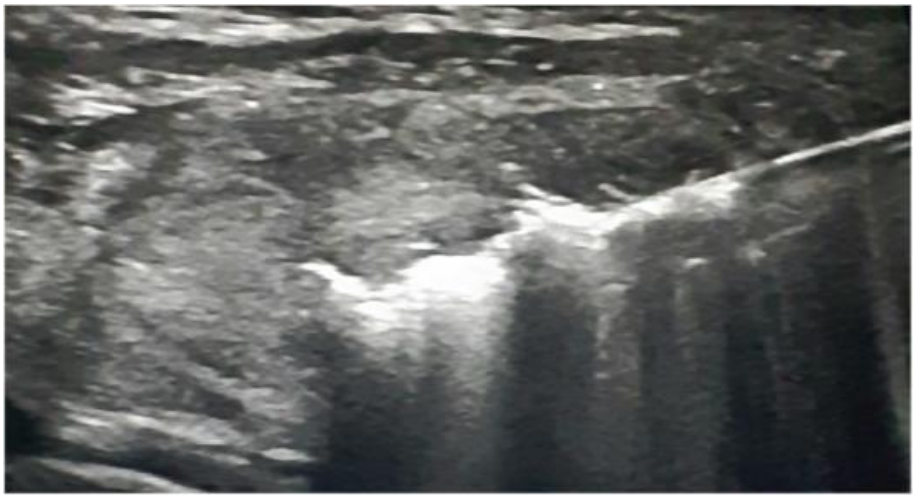

Figure 7. US picture of the RF electrode passing through the thyroid nodule and a transient hyperechoic zone around its tip [20].

Indications and Limitations of Monopolar and Bipolar RFA:

Monopolar RFA is the most commonly used system in thyroid ablation. In this system, electrical current passes from the electrode through the patient's body to grounding pads, creating heat around the active electrode tip. It is effective and widely available, but it requires proper placement of grounding pads and caution in patients with implanted electrical devices, because electrical current may theoretically interfere with pacemakers, defibrillators, or cochlear implants [19]. (Figure 7).

Bipolar RFA confines the electrical current between electrodes and may reduce the spread of current through the body. This can be useful in selected patients where monopolar current is relatively contraindicated, such as patients with certain implanted devices [3].

Patient Selection for Thyroid RFA:

The typical candidate has a benign thyroid nodule causing compressive symptoms, cosmetic complaint, or progressive enlargement, with cytological confirmation of benignity and ultrasound features not suspicious for malignancy. [19].

RFA is especially suitable for patients who wish to avoid surgery, general anesthesia, a visible neck scar, prolonged hospitalization, or unnecessary removal of normal thyroid tissue. [3].

Pre-Procedural Evaluation before RFA:

It includes clinical assessment, ultrasound mapping, cytological confirmation, thyroid function assessment, coagulation assessment, review of antiplatelet or anticoagulant medications, and evaluation of voice symptoms when present. The evaluation should also identify nodules close to critical structures where hydrodissection or modified technique may be needed [19,3].

Clinical Assessment:

Clinical assessment before RFA should document symptom severity, cosmetic concern, dysphagia, neck pressure, foreign body sensation, pain, visible swelling, cough, voice symptoms, previous neck surgery, comorbidities, medication use, anticoagulant intake, and patient preference. [19].

Thyroid Ultrasound:

Thyroid ultrasound is essential before RFA because it defines nodule size, site, composition, vascularity, capsule relation, proximity to critical structures, and presence or absence of suspicious lymph nodes. [3].

Nodules close to the recurrent laryngeal nerve region, carotid sheath, esophagus, trachea, skin, or strap muscles may require hydrodissection or conservative ablation near the dangerous margin. [19].

Cytological Confirmation:

Fine-needle aspiration or core-needle biopsy is used to confirm that the nodule is benign before ablation. [3].

Thyroid Function Assessment:

Thyroid function assessment before RFA includes TSH, free T3, and free T4. These tests are important because thyroid nodules may be non-functioning, autonomously functioning, or associated with background thyroid disease. If TSH is suppressed, thyroid scintigraphy may be needed to identify an autonomously functioning nodule and to guide expectations regarding biochemical response after ablation [3].

Indirect Laryngoscopy:

Baseline laryngeal assessment helps distinguish pre-existing vocal cord dysfunction from post-procedural nerve injury [21].

Radiofrequency Ablation Technique:

Thyroid RFA is usually performed under ultrasound guidance as an outpatient or short-stay procedure. Local anesthesia is commonly used, sometimes with mild sedation, while the patient remains able to report pain, voice change, cough, or other warning symptoms during the procedure. The electrode is inserted into the nodule under real-time ultrasound visualization, and energy is applied while the operator monitors the electrode tip and echogenic ablation zone [3].

The standard technique divides the nodule conceptually into multiple small ablation units. The electrode tip is usually placed first in the deepest and most remote part of the nodule, then moved gradually from one unit to another as echogenic change appears.[21,3].

Approach Methods for Thyroid RFA:

The electrode approach is selected according to nodule position, size, shape, vascularity, and relation to adjacent structures. Common approaches include the transisthmic approach, craniocaudal approach, and lateral approach. The safest approach is the one that allows continuous visualization of the electrode tip, stable electrode control, and adequate distance from the recurrent laryngeal nerve, vagus nerve, trachea, esophagus, carotid artery, internal jugular vein, and skin [3]. (Figure 8).

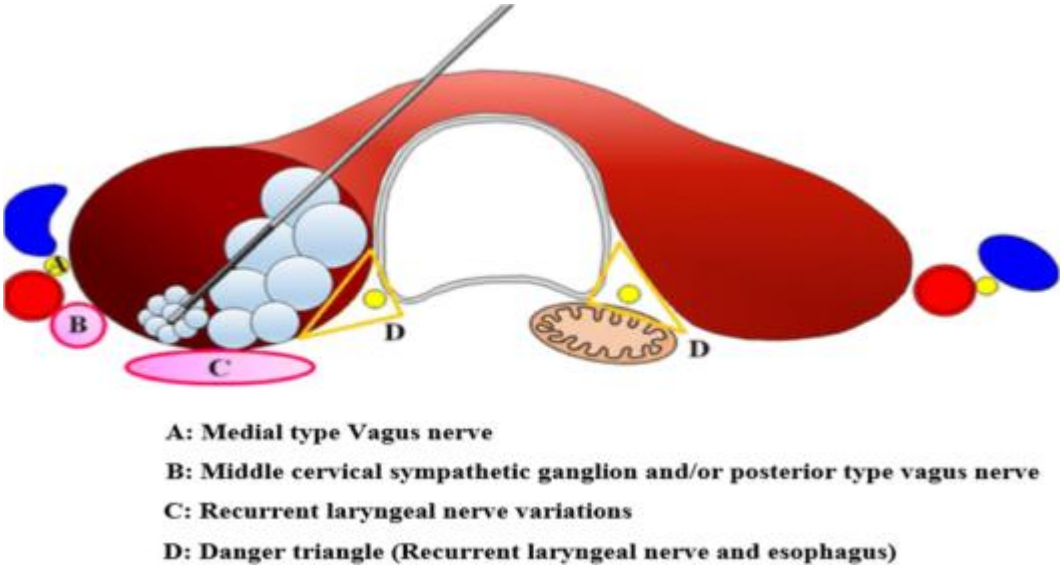

Figure 8. Schema of the trans-isthmic approach and the moving shot technique [20]

Transisthmic Approach:

The transisthmic approach introduces the electrode through the isthmus from the medial side toward the target nodule. It allows a long segment of the electrode to remain inside thyroid tissue, which improves stability and reduces sudden electrode movement. It also helps the operator maintain continuous ultrasound visualization of the active tip during ablation [3]. (Figure 8).

It is particularly useful when the nodule can be reached from the midline without crossing major vessels or dangerous spaces. [22].

Craniocaudal Approach:

The craniocaudal approach introduces the electrode along a superior-to-inferior or inferior-to-superior axis. It may be useful for elongated nodules, upper pole nodules, lower pole nodules, or nodules that cannot be treated adequately through a standard transisthmic path. [22].

Lateral Approach:

The lateral approach introduces the electrode from the side of the neck toward the thyroid nodule. It can be useful when the transisthmic route is not feasible, especially for certain lateral or posterior nodules. However, the lateral path may pass closer to the carotid sheath, which contains the common carotid artery, internal jugular vein, and vagus nerve [19].

Moving-Shot Technique:

Instead of keeping the electrode fixed in one location, the operator divides the nodule into multiple ablation units and treats each unit sequentially. Peripheral units are usually smaller because they are close to the capsule and adjacent danger structures, while central units may be larger [3].

The electrode tip is usually placed first in the deepest and most remote part of the nodule, then withdrawn stepwise toward the superficial portion. [21,3].

Macroscopic Phenomena during Thyroid RFA:

The most important real-time sign is the appearance of a transient echogenic zone around the electrode tip, caused mainly by gas microbubble formation within heated tissue. This echogenic change helps the operator recognize that a specific ablation unit has been treated [3].

Other macroscopic changes include progressive loss of vascularity, tissue contraction, and altered internal texture of the treated nodule. Marginal venous ablation may produce echogenic bubbles in draining veins, while excessive bubble formation may obscure visibility if energy is not controlled. [22].

Ultrasound Monitoring during RFA:

Continuous ultrasound monitoring is essential throughout thyroid RFA. It allows the operator to visualize the electrode tip, confirm the target unit, assess echogenic change, detect early complications, and protect adjacent structures. [3].

Doppler ultrasound is useful before and during ablation because it identifies intranodular vascularity, marginal vessels, carotid sheath structures, and residual viable tissue. It is also useful after ablation to assess whether vascularized tissue remains at the periphery [19,3].

Echogenicity Changes during RFA:

Echogenicity change during RFA is a key real-time marker of tissue heating. The treated area becomes transiently hyperechoic due to microbubble formation, which indicates that thermal energy has affected that unit. [3].

Therefore, follow-up imaging must be interpreted in the context of previous RFA [22,3].

Protection of Critical Structures during RFA:

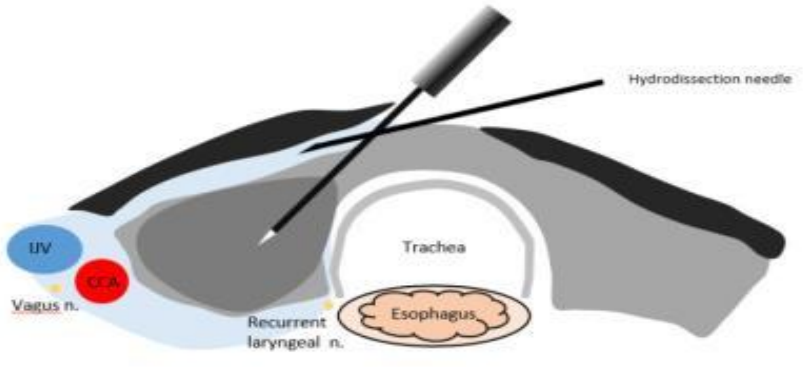

Figure 9. Anterolateral hydrodissection protecting anterior and posterolateral thyroid structures [3]

Hydrodissection is one of the most important safety techniques when the nodule is close to vulnerable structures. [3]. (Figure 9).

Recurrent Laryngeal Nerve:

The recurrent laryngeal nerve is at risk mainly in the tracheoesophageal groove and deep medial thyroid region. [23].

Protection requires cautious ablation near the medial posterior margin, continuous monitoring of patient voice, hydrodissection when possible, and stopping energy delivery if voice change occurs. [3].

Vagus Nerve:

It may be at risk during treatment of lateral or posterolateral nodules, especially when the electrode path passes close to the carotid sheath. [19].

Vagus nerve protection depends on identifying the carotid sheath before puncture, avoiding a dangerous lateral trajectory, and using hydrodissection when the nodule is very close to the sheath. [3].

Trachea:

During RFA, the electrode tip should remain within the nodule and away from the tracheal wall. [3].

Esophagus:

The esophagus is particularly important in posterior and left-sided thyroid nodules. [19].

Protection of the esophagus relies on ultrasound identification, controlled ablation of the posterior margin, and hydrodissection when the esophagus is close to the target. [3].

Common Carotid Artery:

The common carotid artery lies laterally in the carotid sheath and may be close to lateral thyroid nodules. Although the vessel wall is relatively resistant to heat because of blood flow, direct puncture, excessive heating, or ablation too close to the carotid sheath should be avoided. [19].

Internal Jugular Vein:

The internal jugular vein is located laterally within the carotid sheath and may be vulnerable during lateral electrode insertion. It is compressible and can change shape with patient position, respiration, and probe pressure, so Doppler mapping before puncture is important. Venous puncture can lead to bleeding, hematoma, or bruising [19].

Nearby Blood Vessels:

Vascular ablation techniques, including artery-first ablation and marginal venous ablation, may improve volume reduction by decreasing blood supply and reducing the heat-sink effect. [22,3].

Post-RFA Follow-Up:

Post-RFA follow-up begins immediately after the procedure with observation for pain, bleeding, neck swelling, voice change, cough, dyspnea, vasovagal symptoms, and skin changes. [3].

Long-term follow-up evaluates treatment response and detects regrowth. Ultrasound is usually performed at intervals such as 1, 3, 6, and 12 months, then annually when needed. [18,3].

Outcomes of RFA:

The outcomes of RFA include objective ultrasound outcomes and patient-centered outcomes. Objective outcomes include nodule volume reduction, reduced vascularity, disappearance or reduction of viable tissue, and absence of regrowth. Patient-centered outcomes include improvement in compressive symptoms, cosmetic appearance, satisfaction, recovery time, avoidance of scar, and preservation of thyroid function [3].

Outcome assessment should account for nodule size, composition, baseline vascularity, operator experience, number of sessions, and follow-up duration.[24,18].

Nodule Size Reduction:

Nodule size reduction is the main objective ultrasound outcome after RFA. [3]. (Figure 10).

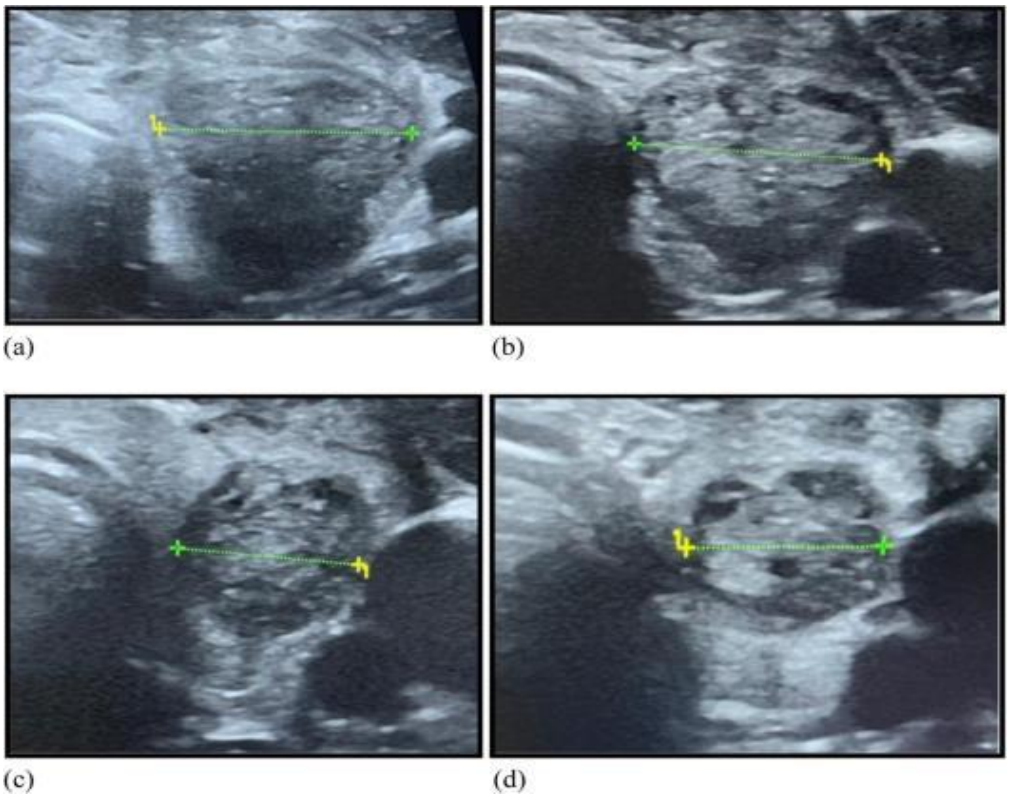

Figure 10. Serial ultrasound before RFA and during follow-up at 1, 3, and 6 months [20] (Figure 10).

Many studies report substantial volume reduction after RFA, commonly around 50% to 80% within 6 to 12 months, with higher reductions over longer follow-up in successfully treated nodules. [18,24].

Symptom Improvement:

Symptom improvement after RFA occurs mainly because the treated nodule shrinks and pressure on surrounding structures decreases. Patients may experience improvement in dysphagia, neck pressure, foreign body sensation, discomfort, choking sensation, and local fullness. [3].

Cosmetic Improvement:

Visible anterior neck swelling may improve as the nodule volume decreases, and RFA avoids the anterior neck scar associated with open thyroid surgery [3]. (Figure 11).

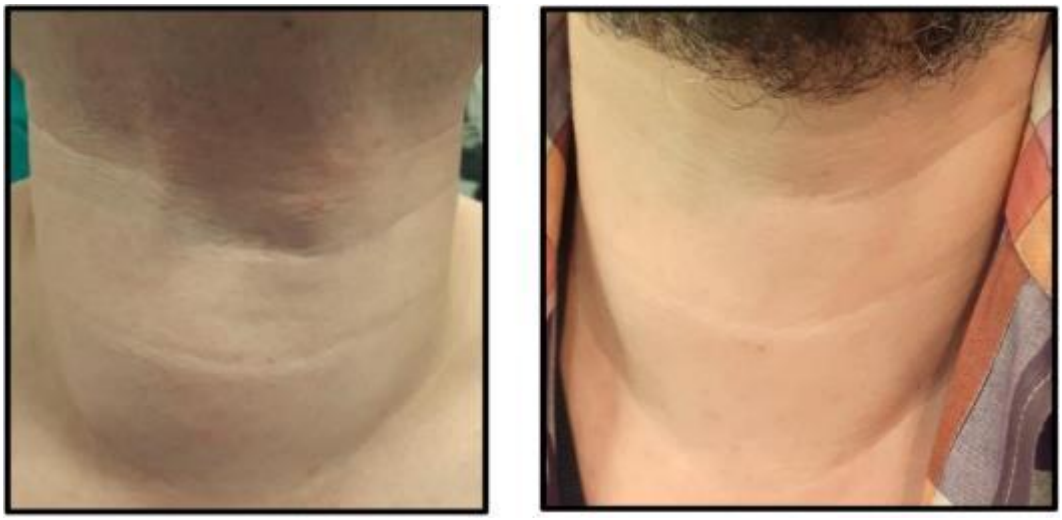

Figure 11. Clinical neck bulging before and after RFA [20]

Thyroid Function Preservation:

Thyroid dysfunction after RFA is uncommon but may occur in selected patients. Risk may be higher in patients with Hashimoto's thyroiditis, higher baseline TSH, treatment of multiple nodules, or limited thyroid reserve [25]. (Figure 11).

Patient Satisfaction:

Patient satisfaction after RFA is influenced by symptom relief, cosmetic improvement, absence of surgical scar, short recovery time, avoidance of general anesthesia, low complication rate, and preservation of thyroid function. Patients often value the ability to return quickly to daily activities, especially when treatment is performed as an outpatient procedure [18].

Complications of RFA:

RFA has a favorable safety profile when performed by trained operators using proper patient selection and ultrasound-guided technique. [23].

Minor complications include pain, small hematoma, bruising, cough, transient edema, vasovagal reaction, and temporary discomfort. Major complications include significant voice change, nodular rupture, major hematoma, skin burn, nerve injury, and rare permanent hypothyroidism.

Pain:

Pain is one of the most common side effects during RFA. It may occur when heat reaches the thyroid capsule, strap muscles, skin, or nearby sensory nerves. [3].

Severe or sudden pain should not be ignored because it may indicate ablation too close to sensitive structures or early complication3 [23].

Hematoma:

Most hematomas are small and resolve with compression and observation, but larger hematomas require close monitoring because neck swelling can affect comfort and, rarely, airway safety [3].

Skin Burn:

Skin burn is an uncommon but important heat-related complication of RFA. It occurs when the ablation zone is too close to the skin surface or when heat tracks along the electrode path [23].

Nodular Rupture:

Nodular rupture is an uncommon but recognized complication after RFA. It usually presents as sudden painful neck swelling days to months after the procedure and may be related to breakdown of the treated nodule capsule, inflammatory reaction, or leakage of necrotic material into surrounding tissues. Ultrasound can help diagnose rupture by showing capsular disruption and perinodular inflammatory change [23].

Most cases can be managed conservatively with analgesics, anti-inflammatory treatment, antibiotics when infection is suspected, and observation. Severe cases with abscess formation, persistent pain, or mass effect may require drainage or surgery. [26].

Voice Changes:

Voice changes after RFA may occur due to thermal irritation or injury of the recurrent laryngeal nerve, vagus nerve, or other laryngeal-related neural structures. [23].

Hypothyroidism:

Hypothyroidism after RFA is rare because the procedure targets the nodule and generally preserves normal thyroid tissue [3].

Comparison between RFA and Surgical Intervention:

RFA and surgery differ fundamentally in treatment mechanism. Surgery removes the target thyroid tissue immediately and provides complete histopathology, while RFA destroys the nodule in place and produces gradual shrinkage. [18].

The comparison should be interpreted according to patient selection. Surgery is appropriate for suspicious, malignant, indeterminate, very large, retrosternal, or diagnostically uncertain nodules, while RFA is appropriate for selected benign nodules that are symptomatic or cosmetically problematic. [19,5].

Efficacy:

Surgery is highly effective for immediate removal of the target lobe or nodule-bearing tissue. [2].

RFA achieves efficacy through volume reduction rather than excision. [3,24].

Safety:

RFA generally has a favorable safety profile because it avoids general anesthesia, open incision, flap elevation, and surgical dissection around parathyroid glands and laryngeal nerves. [23].

Surgical risks include hematoma, wound infection, visible scar, hypocalcaemia, recurrent laryngeal nerve injury, superior laryngeal nerve injury, postoperative pain, and hypothyroidism after lobectomy. [2,18].

Postoperative Complications:

Pain:

Pain after surgery is usually related to skin incision, flap elevation, strap muscle retraction, thyroid dissection, wound closure, and postoperative inflammation. [2].

Pain during RFA is usually more localized and related to thermal irritation of the capsule, skin, muscles, or nearby sensory structures. This makes RFA less painful for many patients, although pain remains an important intra-procedural warning sign [3,23].

Hospital Stay:

Surgery often requires postoperative observation for bleeding, airway safety, pain control, voice assessment, and calcium monitoring when indicated [2].

RFA is usually performed as an outpatient procedure with short post-procedure observation. [3,18].

Skin Scar or Burn:

Surgery produces an anterior neck incision, usually placed in a low transverse skin crease to reduce visibility. [2].

RFA avoids a surgical scar because it is performed through a needle puncture. [23,3].

Thyroid Function Changes: RFA usually preserves thyroid function because it ablates the nodule while leaving most normal thyroid tissue intact [25,3].

Voice Changes:

Voice changes after surgery may result from recurrent laryngeal nerve injury, external branch of superior laryngeal nerve injury, intubation-related irritation, edema, strap muscle dysfunction, or scar-related changes. [2].

Voice changes after RFA are usually related to thermal irritation or injury of the recurrent laryngeal nerve or vagus nerve. [23,19].

Patient Satisfaction:

Patient satisfaction after RFA may be high because the procedure is minimally invasive, avoids a visible scar, is usually outpatient, preserves thyroid tissue, and provides improvement in symptoms and cosmetic appearance over time. Satisfaction is strongest when patients understand that shrinkage is gradual and that follow-up is required [18].

Recurrence:

After surgery, recurrence of the treated nodule is uncommon if the affected lobe is removed, but new nodules may develop in the remaining thyroid tissue. [2].

After RFA, recurrence is usually described as regrowth of treated tissue or persistence of residual viable tissue, especially at the nodule margin. [3,24].

References

1. **Zamora, E., Khare, S., & Cassaro, S. (2023):** Thyroid nodule. In StatPearls [Internet]. StatPearls Publishing.
2. **Biello, A., Kinberg, E., Menon, G. *et al.* (2024):** Thyroidectomy. In StatPearls [Internet]. StatPearls Publishing.
3. **Ferraro, T., Sajid, S., Hodak, S. *et al.* (2024):** Thyroid nodule rupture after radiofrequency ablation: Case report and literature review. Frontiers in Endocrinology, 15, Article 1355383. https://doi.org/10.3389/fendo.2024.1355383
4. **Han, M., & Fan, F. (2023):** Bethesda system for reporting thyroid cytopathology – An updated review. Journal of Clinical and Translational Pathology, 3(2), 84–98.
5. **Durante, C., Hegedüs, L., Czarniecka, A. *et al.* (2023):** 2023 European Thyroid Association Clinical Practice Guidelines for thyroid nodule management. European Thyroid Journal, 12(5), Article e230067. https://doi.org/10.1530/ETJ-23-0067
6. **Lee, E., Park, Y., Jung, C. *et al.* (2024):** A narrative review of the 2023 Korean Thyroid Association management guideline for patients with thyroid nodules. Endocrinology and Metabolism, 39(1), 61–72.
7. **Rago, T., & Vitti, P. (2022):** Risk stratification of thyroid nodules: From ultrasound features to TIRADS. Cancers, 14(3), 717.
8. **Lee, M., Na, D., Joo, L. *et al.* (2023):** Standardized imaging and reporting for thyroid ultrasound: Korean Society of Thyroid Radiology consensus statement and recommendation. Korean Journal of Radiology, 24(1), 22–38.
9. **Chan, W., Wong, K., Yau, C. *et al.* (2024):** Novel and advanced ultrasound techniques for thyroid nodule diagnosis and treatment. Endocrinology and Metabolism. Advance online publication. https://doi.org/10.3803/EnM.2024.1917

10. **Issa, P., Cironi, K., Rezvani, L. *et al.* (2024):** Radiofrequency ablation of thyroid nodules: A clinical review of treatment complications. Gland Surgery, 13(1), 77–86. https://doi.org/10.21037/gs-22-539
11. **Aung, H., Burud, I., Thanu, A. *et al.* (2024):** Relation of external branch of the superior laryngeal nerve and superior thyroid artery: A systematic review and meta-analysis. Annals of Thyroid, 9, 6.
12. **Ng, S., Li, H., Chan, J. *et al.* (2020):** A useful landmark to locate the external branch of the superior laryngeal nerve during thyroidectomy. Gland Surgery, 9(3), 647–653.
13. **Schneider, R., Machens, A., Lorenz, K. *et al.* (2020):** Intraoperative nerve monitoring in thyroid surgery—Shifting current paradigms. Gland Surgery, 9(Suppl 2), S120–S125.
14. **Priya, S., Garg, S., & Dandekar, M. (2021):** Intraoperative monitoring of the recurrent laryngeal nerve in surgeries for thyroid cancer: A review. Journal of Cancer Metastasis and Treatment, 7, Article N-A.
15. **Cooper, D., Kaur, H., Griffin, A. *et al.* (2024):** Hypothyroidism after hemithyroidectomy: A systematic review and meta-analysis. Thyroid Research, 17, 18. https://doi.org/10.1186/s13044-024-00200-z
16. **Abd El-Galil, M., Ali, A., Botros, R. *et al.* (2021):** Efficacy and safety of ultrasound (US)-guided radiofrequency ablation of benign thyroid nodules. Egyptian Journal of Radiology and Nuclear Medicine, 52(1), 57.
17. **Mauri, G., Pacella, C., Papini, E. *et al.* (2022):** Minimally-invasive treatments for benign thyroid nodules: Recommendations for information to patients and referring physicians by the Italian Minimally-Invasive Treatments of the Thyroid group. Endocrine, 76, 1–5. https://doi.org/10.1007/s12020-022-03005-y
18. **Lui, M., & Patel, K. (2024):** Current guidelines for the application of radiofrequency ablation for thyroid nodules: A narrative review. Gland Surgery, 13(1), 59–69. https://doi.org/ 10.21037/gs-23-18
19. **Sinclair, C., Baek, J., Hands, K. *et al.* (2023):** General principles for the safe performance, training, and adoption of ablation techniques for benign thyroid nodules: An American Thyroid Association statement. Thyroid, 33(10), 1150–1170. https://doi.org/10.1089/thy.2023.0281